

Rendu Osler Weber Syndrome, a case report and review

Danae Álvarez¹, Catalina Silva², Javier Arellano³

RESUMEN

La telangiectasia hemorrágica hereditaria (THH) o síndrome Rendu Osler Weber es un trastorno autosómico dominante que lleva a la formación anormal de vasos sanguíneos y se manifiesta como telangiectasias y malformaciones arteriovenosas en piel y órganos internos. Mujer de 72 años con antecedentes de hipertensión arterial, anemia ferropénica e hipertensión pulmonar en tratamiento. Es derivada a dermatología por la presencia durante años de lesiones asintomáticas en cara y manos. Refiere 4 episodios de epistaxis durante su vida y no tiene historia familiar de patologías dermatológicas. Al examen se observan múltiples máculas eritemato-violáceas, con vitropresión positiva, algunas conformadas por telangiectasias, localizadas en la región malar, frente, lengua y ambas palmas. Se excluyó compromiso hepático, pero se encontraron lesiones vasculares en estómago y duodeno. Con estos antecedentes, se confirmó el diagnóstico de THH. La THH es un diagnóstico clínico basado en los criterios de Curaçao: epistaxis, telangiectasias, lesiones viscerales e historia familiar. Desde el punto de vista dermatológico, se presenta con telangiectasias en palmas, dedos, labios y lengua. Aunque la epistaxis u otras presentaciones pueden ser las manifestaciones más incapacitantes o peligrosas, las telangiectasias extranasales pueden ser más importantes para el paciente, llevándolo a consultar a dermatología. Los dermatólogos deben considerar este síndrome, a pesar de su baja incidencia reportada, debido a sus posibles complicaciones. El tratamiento es sólo paliativo, sin consenso sobre la mejor opción de manejo. Es esencial promover un control a largo plazo de la enfermedad.

Palabras claves: Síndrome Rendu Osler Weber; Telangiectasia hemorrágica hereditaria, telangiectasia, malformación vascular

SUMMARY

Hereditary hemorrhagic telangiectasia (HHT) or Rendu Osler Weber syndrome is an autosomal dominant disorder that leads to abnormal blood vessels formation. It manifests as telangiectasias and arteriovenous malformations in the skin and internal organs. A 72-year-old female patient with previous medical history of hypertension, iron deficiency anemia, and pulmonary hypertension in treatment was referred to our clinic due to the presence of asymptomatic acral lesions. She reported only four epistaxis events throughout her life, and had no family history bleeding. Examination showed multiple, blanching, erythematous-violaceous macules. On the malar region, forehead, tongue and palms, some telangiectasias were grouped. No hepatic lesions were found, however, stomach and duodenum vascular malformations were found after workup; prompting the diagnosis of HHT.

HHT diagnosis is made clinically based on the Curaçao criteria: epistaxis, telangiectasias, visceral lesions and family history. From a dermatological point of view, it is presented with telangiectases in palms, fingers, lips and tongue. However, epistaxis or other vascular malformations may be life-threatening. Dermatologists should be aware of the existence of HHT, despite its low reported incidence, due to its frequent cutaneous manifestations and potential complications. Treatment is only palliative, with no consensus on the best management option. It is essential to promote long-term control of the disease.

Key words: Rendu Osler Weber Syndrome, Hereditary hemorrhagic telangiectasia, telangiectasia, vascular malformation

¹Residente Dermatología, Universidad de Chile, Santiago, Chile

²Médico Cirujano, Universidad de los Andes, Santiago, Chile. ³Jefe

Departamento Dermatología, Hospital San Borja Arriarán, Santiago, Chile

Correspondencia: Danae Álvarez. Correo electrónico: mdanadoc77@gmail.com Celular: +56 9 8428 4129. Dirección: Avenida El Bosque 701, depto 603 Providencia, Santiago de Chile. Código Postal: 7510273.

Hereditary hemorrhagic telangiectasia (HHT) is an autosomal-dominant disorder that leads to an abnormal blood vessel formation.^{1,2} It is also known as Rendu Osler Weber Syndrome because Rendu published the first report on HHT in 1896, followed by Osler in 1901 and Weber in 1907.^{3,4} Its prevalence ranges from 1:5,000 to 1:10,000,^{1,3,5} homogeneously distributed by race and gender.⁶ Generally, the diagnosis is not expected until adolescence or later on in most patients, but there is no age limit. This syndrome manifests as telangiectases and arteriovenous malformations (AVMs). Telangiectases occur on mucocutaneous surfaces (i.e., nose, gastrointestinal (GI) tract and skin); AVMs develop in larger organ system (i.e. lungs, liver and brain).^{1,2,4} Histologically, the venules are dilated and lack contractile elastic fibers, predisposing them to bleed.⁷

CASE REPORT

72-year-old female with previous history of hypertension and iron deficiency anemia. Also diagnosed with pulmonary hypertension the previous year, secondary to arteriovenous malformations. All pathologies were under treatment. She was referred to dermatology for the presence of asymptomatic face and hands lesions. She had no family history of dermatological pathologies and reported only four epistaxis events throughout her life. The examination showed multiple erythematous-violet macules that blanched when pressed upon, some conformed by grouped telangiectases, located on the malar region, forehead, tongue and palms. A complete study was performed: upper endoscopy and colonoscopy found vascular lesions in the stomach and duodenum. The abdominal ultrasound excluded hepatic anomalies. With this background, the diagnosis of HHT was confirmed. The patient maintained a multidisciplinary management. Dermatological treatment was offered, but she denied the treatment.

DISCUSSION

HHT is caused by mutations in at least one of the 3 genes involved in the transforming growth factor-beta (TGF- β) signaling pathway. Endoglin, Activin A receptor type II-like 1, and MADH4/SMAD4 mutations caused HHT type 1, HHT type 2 and the combined Juvenile Polyposis/HHT syndrome, respectively. The-

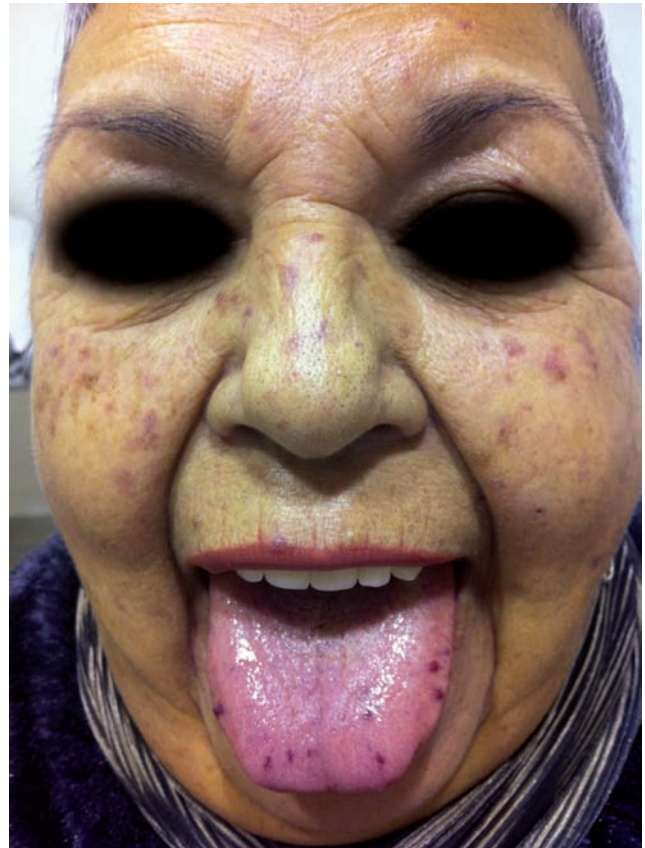


Figure 1
Multiple telangiectases on the face, with typical tongue compromise.

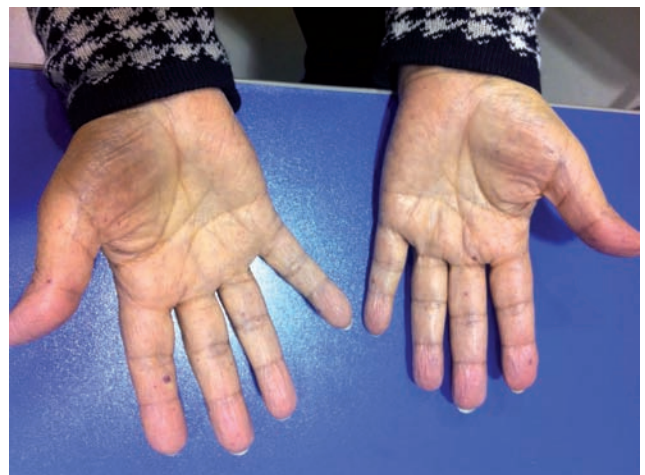

Figure 2
Symmetrical telangiectasic macules are observed in both palms..

Table 1

Differential diagnosis of telangiectasia

| Differential diagnosis | Features |
|---|--|
| Associated with systemic diseases | |
| Lupus erythematosus | Malar rash, photosensitivity, discoid rash, and alopecia are cutaneous diagnostic criteria. Telangiectases can be present, but are not specific. |
| Dermatomyositis | Telangiectases are typically found in sun-exposed areas. They can be associated with hyperpigmentation and skin atrophy. |
| Scleroderma | Patients may develop telangiectases on the face, mucous membranes, and hands in both limited and diffuse scleroderma, being more frequent in limited scleroderma. |
| Cutaneous mastocytosis (telangiectasia macularis eruptive perstans) | Telangiectatic macules with background color ranging from light to dark brown. Caused by the massive infiltration of mast cells in the upper dermis with dilated capillaries. Usually affects adults. Most cases are limited to the skin of chest and extremities, but systemic involvement may occur. |
| Spider angiomas | Secondary to cirrhosis and pregnancy |
| Non associated with systemic diseases | |
| Ataxia telangiectasia | Autosomal inherited neurodegenerative disorder. Patients show progressive ataxia due to cerebellar degeneration as well as cutaneous and ocular telangiectasia. |
| Benign hereditary telangiectasia | Inherited presence of asymptomatic telangiectasia on skin and lips, randomly distributed. It is an idiopathic or primary telangiectasia developed during childhood, possibly at birth, without systemic lesions. |
| Generalized essential telangiectasia | Affects primarily the lower extremities in women within 40-50 years of age. Unknown cause and can progress affecting abdomen and upper extremities. |
| Rosacea | Presence of face telangiectases associated with basal erythema and flushing with determined triggers. |

re are two further unidentified genes that can cause HHT, but 5-10% of the patients currently have unknown genetic cause.^{5,6} Despite the available genetic information, controversy over disease pathogenesis still exists. It is suggested that additional factors may be involved. One of the triggers factors could be a vascular injury with the resulting presence of vascular endothelial growth factor (VEGF).^{1,8}

HHT is a clinical diagnosis based on the Curaçao criteria, developed in 1999.^{1,2,6}

1. Epistaxis: spontaneous, recurrent.
2. Telangiectases: multiple, located in lips, oral cavity, fingers, nose.
3. Visceral lesions: GI telangiectases and pulmonary, hepatic, cerebral and/or spinal AVM.
4. Family history: a first-degree relative with HHT.

Three criteria indicate a certain diagnosis of HHT.

Two criteria make a possible case. The patient met the first three criteria. She does not have family history, which is possible because there is 20% where there is no family history.⁶

There is risk of missing clinical diagnosis in children and young adults, because of the age-related penetrance of HHT. Here lies one of the cardinal benefits of genetic testing, although currently available genetic techniques detection rate is approximately 85%.¹ When considering this diagnosis, other diseases have to be ruled out. (Table 1)⁹

1) Epistaxis

Is the most common symptom, presenting in up to 98% of patients.⁷ It has a wide range of severity and tends to worsen with age, but there are still patients that will not suffer from nosebleeds. These patients may mistakenly believe that they do not have HHT.

The main goal in management is to reduce chronic nasal bleeding through the use of saline rinses and humidification, lubricants, and estrogen (topic or systemic). Other treatments are Tamoxifen, Sesame/Rose Geranium oil, bevacizumab, timolol, among others.⁷ Laser coagulation, Septodermoplasty, Young procedure, and embolization are also an option, but not as first-line treatment.^{1,2,7}

2) Dermatologic manifestations

HHT presents mucocutaneous macular telangiectases. They are bright red to purple and blanch with pressure, with 1 to 3 mm of diameter. They generally appear by age 30 and increase in number along with age. Telangiectases can occur anywhere on the skin, but palms and fingers are the only places affected in 71% of patients, lips and tongue in 66% and 20 to 40% have palms, fingers, lips and tongue affected, compatible with the case we are reporting.^{2,6} Laser systems (pulsed dye laser, argon laser, potassium titanyl phosphate laser and Nd:YAG laser) or intense pulsed light (IPL) have been applied to treat telangiectases.³

3) Pulmonary manifestations

These occur because of pulmonary AVMs and fistulas, present in 50% of the patients. Conversely, HHT is the underlying cause in nearly 80% of patients who have pulmonary AVMs. Therefore, HHT should be considered in any patient diagnosed with a pulmonary AVM. Pulmonary manifestations include hemoptysis, hemothorax, right-to-left-shunt (paradoxical emboli, found in 40-50% of patients). In 8% of patients, massive pulmonary hemorrhage can occur. Other symptoms include hypoxia, dyspnea, cyanosis, polycythemia, clubbing of the distal phalange and pulmonary hypertension, like the present case. All HHT patients should screen for pulmonary AVMs to avoid life-threatening complications, through a contrast echocardiography (bubble echocardiography). AVMs can be successfully embolized with coils, but it is a transitory fix, requiring continued surveillance. Patients with AVMs, as well as those who have not yet been screened, should receive antibiotic prophylaxis before any "dirty" medical procedure.^{1,2,6}

4) Central nervous system (CNS) manifestations

AVMs, arteriovenous fistulas and telangiectases are the most common CNS malformation. It is estimated that

8-41% of patients with HHT will present some neurological complication, such as hemorrhage, headache, seizures, hydrocephalus, cognitive deficits, etc. Hemorrhage can lead to long-term disability or death, therefore all patients should screen for CNS lesions (MRI is considered the test of choice) and if it is done, obliteration is generally required (embolization, microsurgery, stereotactic radiation).^{1,2,6}

5) GI manifestations

Telangiectases can be found anywhere in the GI tract. Stomach and small bowel are mainly affected in approximately 80% of patients, but only 25% of them will develop symptomatic GI bleeding, which usually presents at the age of 50, generally in women.^{1,2,6} Bleeding tends to be persistent and progressive, and iron deficiency anemia is seen in nearly 30% of patients. The source of GI bleeding is usually confirmed by esophagogastroduodenoscopy or colonoscopy.^{1,4,6} The management of GI bleeding involves anemia treatment and therapies to reduce chronic bleeding, using hormones, antifibrinolytics, angiogenesis inhibitors, endoscopic treatments, among others. There is no evidence to recommend one therapy over another.^{1,2}

6) Hepatic manifestations

Hepatic venous malformations can be found in almost 80% of patients, but only about 8% of these patients will develop symptomatic disease, even with grossly abnormal imaging studies.^{1,2,4} AVMs can lead to portal hypertension, biliary disease, and high rate of cardiac failure. Doppler ultrasonography is currently considered the first line screening modality. Magnetic resonance imaging (MRI) and computed tomography can also be used. Liver biopsy should not be performed in patients with suspected AVMs. Treatment is only recommended for symptomatic patients and depends on the type of complication. The accumulative evidence has demonstrated significant benefits from antiangiogenic therapy with bevacizumab. Patients who do not respond to medical therapy may be considered for liver transplantation.^{1,2}

CONCLUSION

Today HHT remains under-recognized, leading to a diagnostic delay and life-threatening conditions. Most patients have a normal life expectancy but about 10%

die of complications.^{1,4,6,10} Extranasal telangiectases can be aesthetically annoying or even stigmatizing, leading patients to a dermatologist consult.³ Therefore, dermatologists must have HHT in consideration, have an prompt diagnosis, detect organ vascular malformations and screen first-degree relatives.⁴

REFERENCIAS

1. Parambil JG. Hereditary Hemorrhagic Telangiectasia. *Clin Chest Med.* 2016;37(3):513-521
2. Olitsky SE. Hereditary hemorrhagic telangiectasia: diagnosis and management. *Am Fam Physician.* 2010;82(7):785-790
3. Papaspyrou G, Schick B, Al Kadah B. Nd:YAG Laser Treatment for Extranasal Telangiectasias: A Retrospective Analysis of 38 Patients with Hereditary Hemorrhagic Telangiectasia and Review of the Literature. *ORL J Otorhinolaryngol Relat Spec.* 2016;78(5):245-251
4. Kamath N, Bhatia S, Singh H, Shetty A, Shetty S. Hereditary hemorrhagic telangiectasia. *N Am J Med Sci.* 2015;7(3):125-128
5. Albinana V, Zafra MP, Colau J, et al. Mutation affecting the proximal promoter of Endoglin as the origin of hereditary hemorrhagic telangiectasia type 1. *BMC Med Genet.* 2017;18(1):20
6. Barbosa AB, Hans Filho G, Vicari CF, Medeiros MZ, Couto DV, Takita LC. Rendu-Osler-Weber syndrome: dermatological approach. *An Bras Dermatol.* 2015;90(3 Suppl 1):226-228
7. Chin CJ, Rotenberg BW, Witterick IJ. Epistaxis in hereditary hemorrhagic telangiectasia: an evidence based review of surgical management. *J Otolaryngol Head Neck Surg.* 2016;45:3
8. Park SO, Wankhede M, Lee YJ, et al. Real-time imaging of de novo arteriovenous malformation in a mouse model of hereditary hemorrhagic telangiectasia. *J Clin Invest.* 2009;119(11):3487-3496
9. Rebellato PR, Martins LE, Stella BT, Tokarski MC. A case of benign hereditary telangiectasia without family history. *An Bras Dermatol.* 2017;92(1):162-163
10. Pierucci P, Lenato GM, Suppressa P, et al. A long diagnostic delay in patients with Hereditary Haemorrhagic Telangiectasia: a questionnaire-based retrospective study. *Orphanet J Rare Dis.*